

**GONADIAL ABNORMALITIES IN THE SCIAENID FISH,
PENNAHIA ANEUS (BLOCH)**

By R. S. LAL MOHAN

Central Marine Fisheries Research Institute, Cochin

GONADIAL abnormalities including hermaphroditism have been observed in many Indian fresh water and marine fishes. In marine fishes hermaphroditism was observed by Chacko and Krishnamoorthy (1949) in *Hilsa ilisha*, Prabhu and Raja (1959), Thomas and Raju (1962) in *Rastrelliger canagurta* (Cuvier), Nayak (1959) in *Polynemus heptadactylus* (Cuvier), Raju (1960) and Thomas and Raju (1962) in *Katsuwonus pelamis* (Linnaeus), Rao (1962) in *Rastrelliger canagurta* (Cuvier). Other gonadial abnormalities are reported by Thomas and Raju (1962) in *Katsuwonus pelamis*, Gnanamekalai (1962) in *Sardinella sirm*, Bensam (1964, 1969) and Dhulkhed (1966) in *Sardinella longiceps*.

While working on the biology of *Pennahia aneus* (Bloch) a few abnormal gonads were observed.

Abnormalities in ovaries :

(i) In a fish of total length 171 mm, weighing 61.0 gms. the left ovary was normal, but the right ovary has a constriction above the upper half and the germinal epithelium fails to develop for about 2 cm. After the narrow constriction it develops into a round ovarian tissue. The ovaries were in third stage of development. Stomach was empty. Locality : Mandapam (Palk Bay) ; date of collection 12-9-1968 (Fig. 1A).

(ii) In a fish of 131 mm. total length and weight 33.4 gms., the right ovary was normal but the left ovary was atrophied and half the length of that of right one. The ovary is in third stage, stomach found to be empty.

Locality : Mandapam (Palk Bay) ; Date of collection 17-10-1968 (Fig. 1B).

(iii) Complete atrophy of the left ovary which is represented by the germinal epithelium is seen in a fish of 100 mm., of total length weighing 62.0 gms. Right ovary is normal. The ovary is in third stage of development. Stomach is empty.

Locality : Mandapam (Palk Bay) ; date of collection 9-10-1968 (Fig. 1C).

Abnormalities in testis :

(iv) In a fish of 232 mm. collected from Waltair the right testis is normally developed but the left testis fails to develop and is represented by a thin swollen chord of germinal epithelium. Spermatozooids are found in the right testis.

Locality : Waltair (Trawl net) ; date of collection 10-10-1968 (Fig. 1D).

(v) Another interesting case of abnormality is seen in a fish of 163 mm., total length and weight 46.5 gms. Here the left testis is completely atrophied without

any trace of development and represented by a thin cord of germinal epithelium whereas the right testis is developed only on the lower half in about 2 cm., length. In this part also the testis is not developed normally but as a globular structure instead of the flat elongated structure. The testis has well developed spermat-

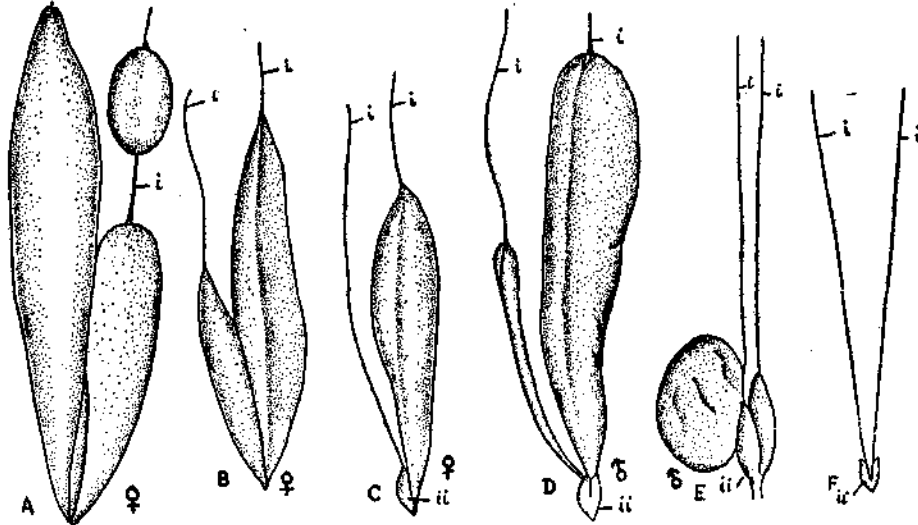


FIG. 1. Abnormal Gonads of *Pennahia aneus* (Bloch).

- A. Abnormal ovary with a constriction on right lobe.
 B. Abnormal ovary with partially atrophied left lobe.
 C. Abnormal ovary with completely atrophied left lobe.
 D. Abnormal testis with atrophied left lobe.
 E. Abnormal testis with completely atrophied right lobe and malformed left lobe.
 F. Asexual gonad
 (i) Chord of Germinal epithelium. (ii) Urinary bladder.

zooids and in fourth stage of development. Melanin pigments, the remnants of nematode parasitic attack were observed in the globular portion of the testis. The stomach is observed empty.

Locality : Mandapam (Palk Bay) ; date of collection 8-10-68 (Fig. 1E).

Asexual gonad :

(vi) Here the absence of gonads is observed. It is interesting to note that such condition is not recorded in fishes. The right and left gonads are represented by a thin chord of epithelium and the microscopic examination of the thin chord fails to show any spermatazooids or oocytes. Evidently it is considered to be an asexual form. This condition is noticed in a fish of 145 mm. of total length weighing 54.7 gms. The stomach was found to be empty but accumulation of fat along the arborescent tubules of the air bladder was observed. Fishes of this size in the same season have well developed gonads in 3-4 stages.

Locality : Mandapam (Palk Bay) ; date of collection 5-7-1968 (Fig. 1F)*.

*All the abnormal specimens are deposited in the Central Marine Fisheries Research Institute Museum (C.M.F.R.I. F. 89-240, B-D).

I am thankful to Dr. R. V. Nair, Deputy Director, Central Marine Fisheries Research Institute, Mandapam Camp for going through this note and offering his comments.

REFERENCES

- BENSAM, P. 1964. On certain gonadal abnormalities met with in the Indian oil sardine *Sardinella longiceps* Val. *J. Mar. biol. Ass. India*, 6(1): 135-142.
- 1969. Further instance of gonadal peculiarities in *Sardinella longiceps* Valenciennes. *Ibid.*, 10(1) : 172-174, also *Adv. Abstr. Contr. Fish. Aquat. Sci. India*, 3 : 167 (1969).
- CHACKO, P. I. AND KRISHNAMOORTHY, B. 1969. Hermaphroditism in the Indian shad *Hilsa ilisha* (Ham.). *Proc. 36th Indian Sci. Congr.*, 167.
- DHULKHED, M. H. 1966. On an unusual ovary of the Indian oil sardine *Sardinella longiceps* Val. *J. Mar. biol. Ass. India*, 7(1) : 210-212 (1965).
- GNANAMEKALAI, A. G. 1962. An instance of gonadal abnormalities in *Sardinella sirm.* *Madras J. Fish.*, 1(1) : 40.
- NAYAK, P. D. 1959. Occurrence of hermaphroditism in *Polynemus heptadactylus* Cuv. & Val. *J. Mar. biol. Ass. India*, 1(2) : 257-258.
- PRABHU, M. S. AND ANTONY RAJA, B. T. 1959. An instance of hermaphroditism in Indian mackerel *Rastrelliger canagurta* (Cuvier). *Curr. Sci.*, 23(2) : 73-74.
- RAO, K. V. 1962. A note on a hermaphroditic gonad in the Indian mackerel *Rastrelliger canagurta* (Cuvier). *J. Mar. biol. Ass. India*, 4(2) : 241-243.
- RAJU, G. 1960. A case of hermaphroditism and some other gonadal abnormalities in the skipjack *Katsuwonus pelamis* (Linnaeus). *Ibid.*, 2(1) : 95-102.
- THOMAS, P. T. AND RAJU, G. 1962. Gonadal abnormalities in scombroid fishes. *Symposium on Scombroid Fishes*. Marine Biological Association of India, Mandapam Camp, Jan. 1962 Part II : 719-724.